



# Visual Outcome in Traumatic Cataract in Children

## A Author's Affiliation

Dr Amtul Naseer Sami

Prof Asad Aslam Khan

### Corresponding address:

**Dr Amtul Naseer Sami**  
 Associate Professor  
 King Edward Medical University,  
 Lahore Pakistan.

## A Abstract

**Background and Objectives:** Traumatic cataract is one of the most common causes of unocular blindness. In this prospective study, "The visual outcome of traumatic cataract in children", we analyzed the visual prognosis after traumatic cataract extraction in children with intraocular lens implantation.

**Methods:** All 30 consecutive cases of age 16 and fewer than 16, who had traumatic cataract are included in this study. They underwent surgery between May 2010 and May 2011. The cases were prospectively evaluated. This study was conducted in Mayo hospital/COAVS. All the patients were worked up according to the protocol. The follow up period was three months.

**Results:** The study group comprised of 30 cases of traumatic cataract out of which 18 cases (60%) were males and 12 cases (40%) were females. Most of the injuries 23 (77%)

were caused by wire, glass and cutting instruments. All cases had traumatic cataract. Corneal injuries 16 (55.3%) and iris related problems 9 (30%) were the most commonly associated findings. Irrigation aspiration with intraocular lens implantation was performed in these cases. Visual acuity improved from PL-PR+ pre-operatively to 6/18 or above than that in 82.97% of the cases postoperatively.

**Conclusion:** Irrigation aspiration with intraocular lens implantation provides satisfactory visual results in traumatic cataract in children. The main cause for impaired vision was corneal scarring, astigmatism, opacity obscuring the visual axis, retinal detachment and Amblyopia.

**Keywords:** Traumatic Cataract; Blunt Trauma; Penetrating Trauma; Children. Cataract Extraction, Intraocular Lens Implantation, Visual acuity.



## INTRODUCTION

Paediatric traumatic cataract is the one of the leading cause of blindness in the world. The blindness may be due to trauma or amblyopia. Cataract may be an early or late manifestation of ocular trauma. --- Traumatic cataract occurs secondary to blunt or penetrating ocular trauma. Lens abnormalities include loss of transparency of lens and loss of lens position. It is difficult to manage amblyopia as it is estimated that the burden of a disable child is equal to that of ten adult blind persons. Both penetrating and blunt trauma may lead to cataract<sup>1</sup>.

Blunt trauma is responsible for coup and countercoup ocular injury. Coup is the mechanism of direct impact. It is responsible for vossious ring (imprinted iris pigmentation). Countercoup refers to distance injury caused by shockwaves which travel along the line of the concussion. When the anterior surface of the eye is struck bluntly, there is an anterior- posterior shortage of eye ball accompanied by equatorial expansion. Combination of the coup and countercoup along with equatorial expansion are responsible for the resulting blunt ocular injury. It is classically stallate or rosette shape. In penetrating ocular trauma the disruption of lens capsule may lead to cortical changes. Penetrating trauma that directly compromises the lens capsule leads to cortical opacification at the site of injury. If the rent in anterior capsule is small, the cortical cataract can seal itself off and remain localized. When the anterior capsule rent is sufficiently large, the entire lens is rapidly opacified<sup>2</sup>.

The ultimate visual outcome depends upon the type of trauma, extent of trauma and the involvement of ocular structure due to trauma. Lens abnormalities include loss of transparency of lens and loss of lens position. They may be combined and complicated by lens fragmentation or swelling. Traumatic cataract can be caused by the mechanical or non mechanical factors<sup>3</sup>. Approximately 75% of people with trauma induced visual impairment have monocular blindness. The incidence of ocular injuries varies in different parts of the world. A study from India on ocular trauma<sup>3</sup> revealed that the incidence of traumatic cataract is 20.53% and<sup>4</sup> from Pakistan revealed that the incidence of traumatic cataract is 12.9%.

### Aims and Objectives

To study the visual outcome in traumatic cataract in children after removal of lens.

### MATERIAL AND METHOD

This prospective study was conducted at college of College of Allied and Visual Science, Mayo Hospital Lahore. From 01-06-10 to 31-05-11. Thirty (30) patients were analyzed in this study. A comprehensive performa was

designed for this study. After admission to the ward detailed history was taken with particular reference to age, sex and mode of injury, causes and circumstances of trauma. Detailed examination was performed included visual acuity testing, intraocular pressure, Slit lamp biomicroscopy to examine the Cornea for any pathology related to the trauma. Anterior chamber examination only in intact globe for hyphema, hypopyon, lens matter, vitreous and lens. Intra ocular pressure was recorded with Applanation Tonometer, If the intraocular pressure was elevated gonioscopy was performed to look for angle damaged. B.scan was performed to exclude posterior segment pathology. Retinoscopy of normal eye, calculation of power of intraocular lens, fundus examination. X-Ray orbit (AP and Lateral view to exclude intraocular foreign body or fractured bone. An inflammation of the eye was treated with steroid and mydriatics drop. The criteria for selection of patients for surgery and intraocular lens implantation was divided in two groups. In group A patient underwent lens matter aspiration, anterior vitrectomy with intraocular lens implantation. Group B included with lensectomy and vitrectomy without intraocular implantation due to absence of adequate anterior or posterior capsule for implantation of intraocular lens.

### RESULTS

Thirty patients were included in this study. The age of patients ranges from 0-16 years. And the mean age of the subjects were divided in to three groups on the basis of their age. Group A included age range from 0 to 5 years, Group B age range from 6 to 11 years and in Group C age range was 11 to 16 years. 3 (10%) were in group A. 14 (46%) were included in group B and 13 (43.3%) in group C. Right eye involved in eighteen (60%) cases and Left eye involved in twelve (40%). The nature of injury showed that perforating injuries present in twenty two (73.3%) and blunt injuries in eight (26.7%) cases. Cornea was scarred in thirteen (43%) and clear in seventeen (57%) cases. Capsular tear was present in eighteen (60%) and intact capsule in twelve (40%) cases. Irrigation aspiration with intraocular transplantation in twenty four (80%) cases. And lensectomy and vitrectomy in six (20%) cases. The final visual acuity was Perception of light in two (6.6%). Hand movement in two (6.6%). Counting finger in one (3.3%). 6/60 to 6/36 in three (10%) cases. 6/24 to 6/18 in sixteen (53.3%) cases. 6/6 in two (6.6%) cases. The reason for poor visual results were including Corneal scarring in six (20%) cases. Decentred intra ocular lens in four (11.3%) cases. Retinal detachment in three (10%) cases. Macular scar in two (6.6%) cases. Amblyopia developed in two (6.6%) cases

### POST OPERATIVE COMPLICATIONS

Postoperative complications included Post



operative uveitis in three (10%) cases. Hyphema was present in one (3.3%) cases. Shallow anterior chamber in two (6.6%) cases. Striate keratopathy in four (11.3 %) cases. Decentration of intraocular lens in one (3.3%) case.

Pupillary captured in two ( 6.6 %) cases. Up drawn pupil in three (10 %) cases. Visual acuity of 6/12 to 6/9 in four (11.3%) cases.

## DISCUSSION

Traumatic ocular injuries often causes significant visual loss in young patients. It is a leading cause of non-congenital unilateral blindness in children. The development of cataract is a known complication following blunt or penetrating trauma to the eye<sup>5</sup>. The incidence of traumatic cataract reflected in ophthalmic literature varies from 1% to 15% of all ocular injuries<sup>6</sup>. The final visual outcome depends upon type of trauma, extent of lenticular involvement and associated damage to ocular structures. In our country 12.9% of cases of trauma developed traumatic cataract<sup>7</sup>. In India 14% of all cases of cataract in children are due to trauma. Recent advances in therapeutic methods<sup>1</sup> including viscoelastics substances, microsurgical techniques such as vitrectomy, intraocular lens implantation permit better management of injured eyes<sup>8</sup> and good visual prognosis.

In children after removal of traumatic cataract, we face the problem of unocular aphakia. There are various ways to correct aphakia including prescription of aphakic glasses, contact lenses, and intraocular lens implantation. There are various drawbacks for these methods as the Spectacle correction does not help in developing binocular vision due to anisometropia and astigmatism. Contact lenses are also helpful to a certain extent only but in our circumstances it is very difficult to maintain contact lenses in children. A particular problem in children with ocular trauma is the development of amblyopia in the injured eye; the younger the child at the time of visual deprivation, the faster the amblyopia develops<sup>8</sup> the children under the age of 8 years are at particular risk from traumatic cataract<sup>1</sup>.

In literature, male predominance is the commonest feature of eye injuries in children. Male to female ratio is 4:1<sup>3,5</sup>. In current study the ratio is 3:1. This difference may be related to differences in outdoor activity and socioeconomic status. The monocular traumatic cataract in 92 % and unioocular in 8%<sup>8</sup>. We noticed the unilateral involvement in all cases. Ocular trauma in children due to penetrating injuries with sharp objects is more common in 79% of cases<sup>9</sup>. In our study, penetrating injury is the most common mode of injury is penetrating 73.3%. Pre-operative visual acuity was noticed PL+PR+ in 60% of cases and counting finger in 40% of cases.

In literature the variation of visual acuity from PL+ to 6/60<sup>10</sup>. Final visual acuity of 6/6 in 6.6%, 6/9 to 6/12 in 11.3%, 6/18 to 6/36 in 10% and PL+PL+in 6.6%. Other study done by Bejiga et al<sup>11</sup> of traumatic cataract management demonstrated that Visual outcome available for 62 cases and ranged from 6/5 to no perception of light, with one enucleation. Twenty-five patients (34%) achieved visual acuity of 6/12 or better, whereas for 23 (30%) children, visual acuity was reduced to between 6/12 and 6/60. For 14 (19%) individuals however, visual acuity loss was even more significant at <6/60, including four with perception of light or worse. The visual prognosis in traumatic cataract is poor because of concomitant injury to other ocular structures. Churchill AJ et al<sup>12</sup> noticed that the management of traumatic cataract depends on the integrity of posterior capsule, zonules, and associated injury to cornea, uveal tissue and posterior segment. In this study the associated damage includes corneal injuries in the form of scar or opacity seen in 6 cases (20 %). Corneal scarring and opacity affected the visual acuity by obstructing the visual axis and causing astigmatism. Corneal scarring may lead to quantitatively and qualitatively poor vision in our study. Injury to the iris seen in 5 cases (17%) in the form of traumatic mydriasis, iridodialysis and posterior and anterior synchiae. The iris related complication did not greatly affect the visual prognosis. Adherent leucoma was seen in 2 (6.6%) cases, which causes astigmatism and decreased vision due to partial obstruction of visual axis. Valentina et al<sup>13</sup> also noticed that that Visual acuity could not be improved beyond 0.05-0.1 because of corneal scar and postoperative complications such as posterior capsule opacification, intraocular lens decentration, pupil capture, and retinal detachment in one case. Fibrinous uveitis is the most common post operative complication, which may lead to formation of posterior synechia, pupillary block glaucoma and membrane formation. To avoid these complications, patients received intensive steroid in early post operative period and gradually tapered in 3 months The intra-ocular lens was not implanted in 5 cases (20 %) due to lack of capsular support. In our study corneal scarring was present in 4 (13 %) cases it lies on the visual axis of cases which effect on vision. MC Grieshaber et al<sup>14</sup> also noticed that mixed corneoscleral wound was strongly associated with unfavorable outcome, mainly due to phthisis bulbi. Purely sclera and peripheral corneal laceration offer a better prognosis.

In our study the rate of posterior capsular opacification occurred is 9 cases (30%) less than other studies due to surgical posterior capsulotomy and anterior vitrectomy. Valentina<sup>13</sup> also noticed that PCO occurred in 15 (30%) cases. The rate of posterior capsular opacification was higher in children. These cases were advised for Nd-YAG laser capsulotomy. Posterior capsular thickness can be at

best avoided by continuous capsulorrhexis and through cortical wash. Krishnamachary<sup>15</sup> noted 41.66% of posterior capsular thickening in their series, who were treated with Nd: YAG capsulotomy and regained good vision. He noticed that 92% of clinically significant posterior capsule opacification was almost universal (92%) and they were treated with Nd-YAG laser capsulotomy. Our study demonstrated that the majority of eyes with traumatic cataract could be safely rehabilitated with posterior chamber intraocular lens implantation. Post operative visual acuity improves 6/18 or above in 82.97% in others cases vision is not improved due to of post operative complications including corneal scar, corneal opacity obstructing the visual axis and retinal detachment. Other studied. Whereas Gain et al<sup>16</sup> concluded that post operative visual acuity depends on complications. Gupta et al<sup>17</sup> also had good results in children with traumatic cataract. I. Rapport<sup>7</sup> noticed in his study that 58% of the patients regained visual acuity between 6/6 and 6/60.

**CONCLUSION**

The study concluded that the visual outcome is usually good after traumatic cataract in children and can be further improved by intraocular lens implantation for the management of

- 1- Uniocular aphakia.
- 2- Amblyopia can be prevented and can be developed. Binocular single vision in children.

**Table 1**  
The age wise distribution of subjects Age

Age	Distribution
0 - 5 yrs	10.0
6 - 10 yrs	46.7
11 - 16 yrs	43.3
Total	100.0

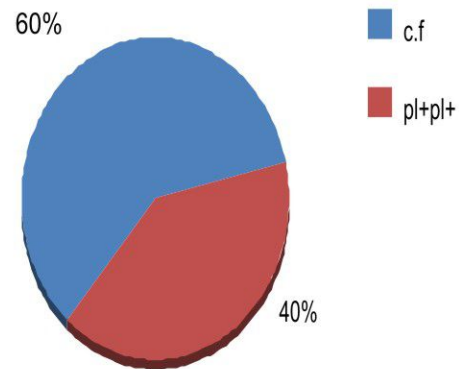
**Table 2**  
Gender incidence (Distribution Sex)

No of cases	Frequency	Percent
Male	21	70.0
Female	9	30.0
Total		100.0

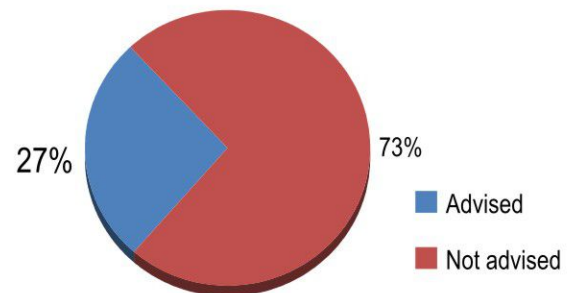
**Table 3**  
Nature of injury

TYPE OF INJURY	Frequency	Percent
Blunt	8	26.7
Perforating	22	73.3
Total	30	100.0

**Fig.4: Best Corrected Visual Acuity (Pre operative)**

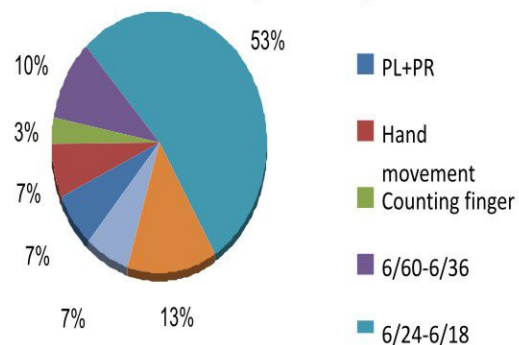


**Fig.5: Patching**



**Fig.6: Visual acuity Three-month (Post operated)**

**Visual acuity Three-month (Post operated )**




**References:**

1. Karim A, Loghari A et al Therapeutic. and prognostic problems of traumatic cataract – Apopros of 45 cases. *Jr of Ophthalmology*, 1998; 21(2): 112-7.
2. Das R, Roy M, Midya A, Roy IS. Intraocular lens implants in traumatic cataract. *Indian J Ophthalmol*. 1989 Apr-Jun;37(2):89-90.
3. Panda A, Kumar S, Das H, Badhu BP. Striving for the perfect surgery in Traumatic cataract following penetrating trauma in a Tertiary care hospital in Eastern Nepal. *J.Nepal Med Assoc* 2007;46 (167):111 12.
4. Khan MD, Kundi N, Mohammad Z, Nazeer AF. A 6.5 year survey of intraocular and intraorbital foreign bodies in the North West Frontier Province, Pakistan. *Br J Ophthalmol* 1987;71:716-719.
5. Chuang LH, Lai CC. Secondary intraocular lens implantation of traumatic cataract in open-globe injury. *Can J Ophthalmol* 2005;40:454–459.
6. Stuffer SE, Ruddle JB, Mackey DA. Rock, paper and scissors? Traumatic paediatric cataract in Victoria 1992-2006. *Clin Experiment Ophthalmol*. 2010 Apr;38(3):237-41.
7. Rapoport I, Romem M, Kinek M, Koval R, Teller J, Belkin M et al. Eye injuries in children in Israel. A nationwide collaborative study. *Arch Ophthalmol*. 1990 Mar;108(3):376-9.
8. Bloemendal H, de Jong W, Jaenicke R, Lubsen NH, Slingsby C, Tardieu A. Ageing and vision: structure, stability and function of lens crystallins. *Prog Biophys Mol Biol*. 2004 Nov;86(3):407-85.
9. Iqbal M, Jan S, Khan MN, Iqbal A, Mohammad S. Pedriatic intraocular lens implantation, complication and visual out come. *Pakistan J Med Research* 2004;43(3).
10. Magne Manjula. Clinical study of traumatic cataract and its management [Dissertation for degree of master of surgery]. Rajiv Gandhi University of health sciences, 2006, Karnataka.Banglore, India.
11. Bejiga A. Causes and visual outcomes of perforating ocular injuries among Ethiopian patients. *Community Eye Health* 2001; 14: 45–6.
12. Churchill AJ, Noble BA, Etschells DE, George NJ. Factors affecting visual outcome in children following uniocular traumatic cataract. *Eye*;1995; 9(3): 285-91.
13. Valentina Lacmanoviæ Lonèar, Ivanka Petric.Valentina Lacmanoviæ Lonèar, Ivanka Petric.Surgical Treatment, clinical outcome, and complications of traumatic cataract: Retrospective Study. *Ophthalmology* 2004; 45(3):310-313.
14. Grieshaber MC, Stagman R, Penetratig eye injuries in South African children: Aetiology and visual outcome.*Eye*.2006; 20; 789-95.
15. Krishnamachary M, Rathi V, Gupta S. Management of traumatic cataract in children. *J Cataract Refract Surg*. 1997;23 Suppl 1:681-7.
16. Gain P, Thuret G, Maugery J. Management of traumatic cataracts. *J Fr Ophtalmol*. 2003 May;26(5):512-20 [Article in French].
17. Gupta AK, Grover AK, Gurha N. Traumatic cataract surgery with intraocular lens implantation in children. *J. Pediatric Ophthalmol Strabismus*. 1992; 29(2): 73-8. 76