



Pars plana vitrectomy for vitreous hemorrhage without and with tamponade of gas to prevent early recurrent vitreous hemorrhage

A Author's Affiliation

Dr. Muhammad Younis Tahir

Dr. Muhammad Arif

Dr. Qasim Lateef

Dr. Najam Iqbal

Prof. Asad Aslam Khan

Correspondence Author:

Muhammad Younis Tahir
 Assistant Professor
 59-B Satellite Town Bahawalpur.

Purpose: to evaluate effect of endo tamponade of non-expansile C3F8 on early post operative vitreous hemorrhage.

Methods: Forty cases selected through OPD in vitreo-retina unit of mayo hospital by non probability convenient sampling and divided randomly in two groups of twenty each by using lottery method. Standard 23 gauge vitrectomy was done in all cases. Group 1 closed in fluid without endo-tamponade while in group 2 endo-tamponade of non expansile gas was given.

Cases were followed for rate of early recurrent vitreous hemorrhage and need for revision surgery in 2 months time

Results: Marked decrease in rate of early vitreous hemorrhage with endo-tamponade of gas. Only 15%-30% developed early VH as compared to 45% to 65% in no tamponade group. About 55% in group 1 and 10% in group 2 were treated with vitreous lavage for non clearing vitreous hemorrhage.

Conclusion: We found endo-tamponade of non-expansile gas much superior to no tamponade at end of PPV for diabetic vitreous hemorrhage. It reduces the rate of revision surgery.



INTRODUCTION

It is common observation that vitreous hemorrhage (VH) persists or recurs after Pars plana vitrectomy (PPV) for proliferative diabetic retinopathy (PDR). In different studies it is reported between 29% to 75%^{1,2}. Hemorrhage may occur as early as during the first few days following surgery to many months or even years later. Almost 67% (Two thirds) of all cases occur during the first 6 months. VH is an important cause of delayed visual recovery and the patient may need to be operated again. Causes of early and late vitreous hemorrhage are different:

Early or persistent hemorrhage may be due to³:

1. Remnants of new vessels or oozing dissected tissues during or after surgery
2. Sclerotomy site bleeding
3. Blood clot lysis
4. Hemorrhage from residual anterior vitreous "shake out bleeding".

Late or recurrent hemorrhage can result from:

1. New vessel growth
2. Recurrent traction on remnant dissected tissue
3. Entry site neovascularization⁴ in which new anterior vessels grow at the inner sclerotomy sites accompanied with traction. This occurrence can be visualized by indirect ophthalmoscopy with deep scleral depression or documented with anterior segment high resolution ultrasonography⁵.

Management of post-operative VH ranges from observation⁶ to timely revision surgery. This depends on a number of factors including the severity and duration of VH, status of the fellow eye and the general condition of the patient. It is estimated that 30 to 50% of patients with postoperative vitreous hemorrhage would need revision surgery⁷.

Different techniques have been used to minimize the occurrence of this complication. For prevention of early post-operative VH, injection of intra-vitreous anti VEGF after and/or at end of surgery, complete removal of peripheral

vitreous and proper cauterization of traumatized blood vessels, use of long acting gas tamponade⁸ have been advocated. Whereas for prevention of late VH laser to peripheral ischemic retina, cryotherapy of vitreous base⁹ and sclerotomy sites is used.

Bevacizumab is a monoclonal antibody against vascular endothelial growth factor which is currently being used in the treatment of proliferative diabetic retinopathy (PDR) and other retinal vascular diseases^{10,11}. Bevacizumab can cause decrease in retinal neovascularization among diabetics; therefore, it has been suggested for intravitreal injection before vitrectomy to decrease the risk of intraoperative and early bleeding¹².

We know that the incidence of per-operative bleeding and chance of residual blood clots can be reduced by injecting bevacizumab intravitreally. We also hypothesize that intra-operative use of long-acting gas could improve recovery from iatrogenic retinal vessel injury in the post-operative period. It may concentrate coagulation factors in vitreous cavity which will gradually help the vessel wall to recover and would thus result in absorption of vitreous opacities due to blood and clots.

Material and methods

This is retrospective interventional comparative study carried out at Vitreo-retina unit of eye ward, Mayo Hospital between Jan 2012 to June 2012. Forty cases selected through OPD by non probability convenient sampling and divided randomly in two groups of twenty each by using lottery method.

Inclusion criteria

1. Vitreous hemorrhage due to proliferative diabetic retinopathy
2. Age between 25 to 60 years
3. No gender discrimination

Exclusion criteria

1. Vitreous hemorrhage complicated by tractional retinal detachment or NVI.
2. History of uncontrolled hypertension, diabetes, hyperlipidemias.
3. Patients on anticoagulation therapy
4. History of coagulation disorders.

5. Patients in whom PPV was being done for reasons other than complications of proliferative diabetic retinopathy e.g. chronic macular edema, epiretinal membrane, or vitreomacular traction (VMT) etc.

Preoperative evaluation included complete ocular examination consisting of measurement of visual acuity and intraocular pressure, slit lamp examination, indirect ophthalmoscopy with scleral depression and Goldman triple mirror examination of peripheral retina. General physical examination was carried out by physician with special check on control of blood pressure and blood sugar level. All record was maintained on prescribed proforma. Informed consent was taken from patients after approval of hospital ethical committee. All patients were operated under local anesthesia and done by two main surgeons in same settings. All cases were given intravitreal injection of bevacizumab (Avastin®) 1.25mg/0.05ml seven days before surgery. We equally divided cases in two groups.

Group 1 received treatment with standard 23 gauge PPV and endolaser whereas Group 2 was treated with standard 23 gauge PPV, endolaser plus endotamponade of C3F8 (12%-15%). Procedure consisted of removing of the new as well as old blood along with fibrovascular tissues as much as possible from all the cases especially blood clots along the peripheral vitreous area were removed as was safely possible. Meticulous suction and inspection for residual bleeding was done at end of surgery. Endo laser was completely done in all possible areas of retina. Hemostasis during the whole procedure was secured by increasing intraocular pressure or by endodiathermy. No eye was treated with cryotherapy. Group 1 cases were closed in fluid without endo tamponade of air or gas while in Group 2 standard procedure of fluid air gas (12% to 15% C3F8) exchange done at end of surgery.

All patients were examined daily during hospital stay and after discharge re- evaluated on Week 1, Week 4, Week 6, and Month 2 postoperatively. On each visit complete examination was carried out including visual acuity, intraocular pressure, slitlamp examination with 90 D, indirect ophthalmoscopy with 20 D and recorded on prescribed proforma. The main outcomes of our study were the incidence as well as the severity of early VH after surgery and need for revision surgery. The option of 6 weeks' time period for follow up was to ensure complete absorption of all the gas from the vitreous. We used the following standard scale based on the Diabetic Retinopathy Study Group grading scale keeping in mind that VH grading is subjective and examiner dependent.²²

Grade 0 is defined as no VH (a clear view throughout).

Grade 1: Mild VH with a good detailed view of the optic disc and macula.

Grade 2: Moderate vitreous hemorrhage with an orange fundus reflex but no fundus details are visible

Grade 3: severe vitreous hemorrhage where no orange fundus reflex and no retinal details can be seen

Results were summarized and prepared using SPSS versions 10.0 for statistical analysis

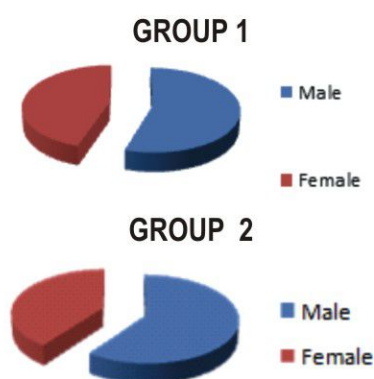
Results

Results are not easy to interpret in case of posterior segment surgery especially when multiple factors are involved in pre-operative, per operative and post operative period. Although we excluded cases with advanced diabetic retinopathy complications but status of macula and retinal vessels in each case have effects on final results.

Main objective of our study was to determine rate and incidence of early VH and need for revision surgery in early post operative period.

In our study we noticed 55% males in Group 1 and 60% males in group 2. Regarding diabetes 70% cases were IDDM in group 1 and 35% cases were with IDDM in group 2. About 75% cases were having DM for more than 10 years in group 1 and 55% in group 2. Clinical characteristics of both groups are compared as follows:

Clinical characteristics of cases in two groups



Characteristics	Group 1	Group 2
No of eyes	20	20
Right eye	13	8
Left eye	7	12
Age (years)	25-60	25-60
Gender		

Male	11(55%)	12(60%)
Female	9(45%)	8(40%)
Types of Diabetes		
IDDM	14(70%)	7(35%)
NIDDM	6(30%)	13(65%)
Duration of Diabetes		
Less than 10 years	5(25%)	9(45%)
More than 10 years	15(75%)	11(55%)

Visual acuity largely depends on status of media including cornea, lens, vitreous and macula but we recorded it on each visit and noticed following results:

Visual Acuity at Selected Time Points
(LogMAR / Approx. Snellen equivalent)

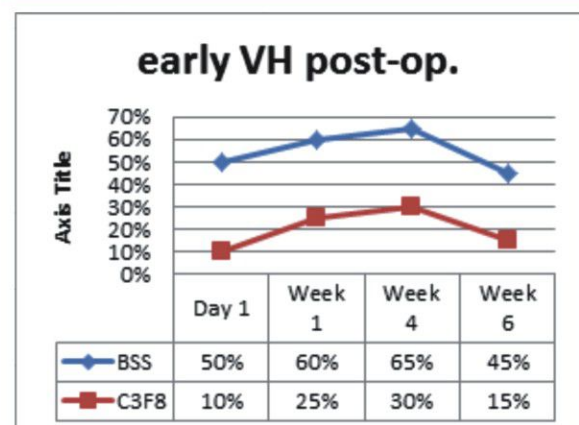
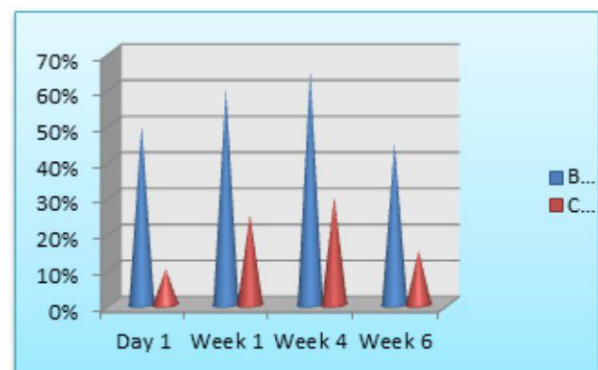
	Group 1	Group 2	P- value
Pre-op (Approx. Snellen)	1.47 ± 0.8 (7/200)	1.72 ± 0.9 (CF 4')	0.128
1 Month Postoperative	1.07 ± 0.9 (20/200 ⁻³)	0.87 ± 0.9 (20/150)	0.230
2 Month Postoperative	0.76 ± 0.8 (20/100 ⁻³)	0.65 ± 0.6 (20/100 ⁻²)	0.993

P values for visual acuity were calculated using Mann-Whitney-Wilcoxon test which revealed no statistically significant difference between groups at any time point.

After infusion, gas was found to occupy 3/4 (75%) of the vitreous cavity on Day 1 after surgery in all the cases. It reduced to about a third (30%) of the vitreous cavity at 2 weeks after surgery, while it was completely reabsorbed at the 6-weeks point of time. Rate and incidence of vitreous hemorrhage in both groups were as follows:

Early vitreous hemorrhage postoperatively in both groups

	Groups	Mild	Moderate	Severe	Total
Day 1	BSS	3	4	3	10(50%)
	C3F8	1	1	Nil	2(10%)
Week 1	BSS	3	5	4	12(60%)
	C3F8	2	3	Nil	5(25%)
Week 4	BSS	6	4	3	13(65%)
	C3F8	3	2	1	6(30%)
Week 6	BSS	4	4	1	9(45%)
	C3F8	1	1	1	3(15%)



P value for early vitreous hemorrhage was 0.298 in group 1 and 0.360 in group 2 with Friedman Test and this is non-significant.

We recorded intraocular pressure on each visit. When intraocular inflammation is settled to some extent and gas dynamics have established IOP readings were as



follows by the end of first week:

Intraocular pressure on Day 7

	Group 1	Group 2
Upto 15mm Hg	12(60%)	4(20%)
Between 16 to 25mm Hg	7(35%)	13(65%)
More than 25 mm	1(5%)	3(15%)

Mean IOP reading was 15.9 mm with standard deviation of 5.2 in group 1 and mean IOP reading in group 2 was 19.3 with standard deviation of 5.29. P value was 0.051 in both groups with independent samples test.

Early vitreous hemorrhage was initially observed for some time. Intravitreal injection avastin was given in moderate and severe vitreous hemorrhage cases. No case developed retinal detachment in each group but vitreous lavage was done in two months time in following number of cases:

Repeated surgery in 2 Months

Required vitreous	11(55%)	2(10%)
Retinal	Nil	Nil

Discussion

Vitreous hemorrhage after surgery is signified by: (1) reduced vision especially in patients with one functional eye only, (2) Difficulty in viewing the fundus during follow up examination when post operative complications e.g. retinal detachment may be missed (3) problems during laser photocoagulation, (4) ghost cell glaucoma, (5) proliferation of fibrovascular tissue in the vitreous cavity due to migration of platelet-derived growth factor (PDGF) and fibrinogen, (6) need to repeat the procedure¹³.

In our study males were predominant in both groups due to more and early exposure to medical facilities in this part of world. We observed raised intraocular pressure in gas tamponade group in initial two weeks time. This was probably due to gas bubble dynamics. All of these cases were treated on medical treatment except one female patient in gas group

having shallow anterior chamber which developed pupil block glaucoma and treated with medical treatment plus laser iridotomy.

As we know visual acuity varies from case to case condition of cornea, lens, vitreous and status of macula preoperatively and post-operatively. We have seen no statistically significant difference in visual acuity between both groups when gas was totally absorbed.

We have noticed marked difference in rate of vitreous hemorrhage in both groups. In group 1 without endo-tamponade about 45% to 65% cases had early vitreous hemorrhage during 6 weeks time period while in group 2 with endo-tamponade of long acting gas C3F8 only 15% to 30% had early vitreous hemorrhage. Other than absence of endo-tamponade this increased incidence of VH in group one may be due to fact that about 70% cases were having IDDM (more than 10 years).

We analyzed the data using Fried man test and found p value of 0.298 in group 1 and p value of 0.360 in group 2 for vitreous hemorrhage. During statistical analysis we found our data is biologically significant but statistically non significant. This may be due to small sample size of our study.

There is great variation in the reported incidence of postoperative VH following vitrectomy for Proliferative Diabetic Retinopathy¹⁴. Two older studies report incidence rates of immediate postoperative VH as 75% and 63%, respectively¹⁴. However, both these studies are more than 20 years old before the use of modern vitrectomy procedures and instruments. In a later study haemorrhage was seen in 75% of cases that had undergone vitrectomy for diabetic retinopathy on the first postoperative day. This, however, cleared spontaneously in most of the cases. On the other hand, hemorrhage occurs in 20–30% of the cases as late as weeks or months following surgery¹⁵. 4% to 38% of these late occurrences require reoperation for persistent vitreous haemorrhages¹⁵. In the majority of cases undergoing air fluid exchange for recurrent or persistent vitreous haemorrhage following vitrectomy, the site of the haemorrhage cannot be found¹⁶.

We cannot directly compare the incidence rates of VH in different studies due to different definitions and grading criteria, we observed an overall rate of revision surgery of about 55% in group 1 and 10% in group 2 with gas tamponade. Our lower incidence rate of re-do surgery may be due to advances in modern vitrectomy and due to alternatives like anti VEGF intravitreal injection the use of which can modify indication for early re-do surgery.

The results of our study, just like any retrospective study, should however be interpreted with caution. We do



have certain limitations regarding control of hypertension. At the same time selection bias, follow-up for a limited time, possible errors in methodology (e.g. lens status, use of Snellen visual acuity) and partial or no masking/blinding of surgeons throughout the operation (due to obvious reasons) may be a source of bias.

Future randomized prospective studies are needed to evaluate fully the use and long-term safety of intravitreal gas tamponade for early postoperative VH and also the extent of visual recovery by this procedure.

Conclusion

Intravitreal tamponade of C3F8 has reduced rate of early postoperative haemorrhage. It can reduce need for revision surgery like vitreous lavage. Further randomized and masked trials are needed errors in methodology (e.g. lens status, use of Snellen visual acuity) and partial or no masking/blinding of surgeons throughout the operation (due to obvious reasons) may be a source of bias.

Future randomized prospective studies are needed to evaluate fully the use and long-term safety of intravitreal gas tamponade for early postoperative VH and also the extent of visual recovery by this procedure.

References

- Schachat AP, Oyakawa RT, Michels RG, Rice TA. Complications of vitreous surgery for diabetic retinopathy II Postoperative complications. *Ophthalmology*. 1983;90(5):522-30
- Tolentino FI, Cajita VN, Gancayco T, Skates S. Vitreous hemorrhage after closed vitrectomy for proliferative diabetic retinopathy. *Ophthalmology*. 1989;96(10):1495-500
- Nakhleh E, Sophie J. Bakri. The Use of Antivasular Endothelial Growth Factor Agents in the Perioperative Period in Diabetic Vitrectomy. *Middle East Afr J Ophthalmol*. 2012 Jan-Mar; 19(1): 83-87.
- West JF, Gregor ZJ. Fibrovascular ingrowth and recurrent haemorrhage following diabetic vitrectomy. *Br J Ophthalmol*. 2000;84:822-5.
- Steel DH, Habib MS, Park S, Hildreth AJ, Owen RI. Entry site neovascularization and vitreous cavity hemorrhage after diabetic vitrectomy. The predictive value of inner sclerostomy site ultrasonography. *Ophthalmology*. 2008;115:525-32.
- Tolentino FI, Cajita VN, Gancayco T, Skates S. Vitreous hemorrhage after closed vitrectomy for proliferative diabetic retinopathy. *Ophthalmology*. 1989;96:1495-500.
- Blankenship GW. Management of vitreous cavity hemorrhage following pars plana vitrectomy for diabetic retinopathy. *Ophthalmology*. 1986; 93:39-44.
- Yang CM, Yeh PT, Yang CH. Intravitreal long-acting gas in the prevention of early postoperative vitreous hemorrhage in diabetic vitrectomy. *Ophthalmology*. 2007;114(4):710-5.
- Neely KA, Scroggs MW, McCuen BW., 2nd Peripheral retinal cryotherapy for postvitrectomy diabetic vitreous hemorrhage in phakic eyes. *Am J Ophthalmol*. 1998;126(1):82-90
- Moradian S, Ahmadi H, Malihi M, et al. Intravitreal bevacizumab in active progressive proliferative diabetic retinopathy. *Graefes Arch ClinExpOphthalmol* 2008; 246:1699-705.
- Jorge R, Costa RA, Calucci D, et al. Intravitreal bevacizumab (Avastin) for persistent new vessels in diabetic retinopathy (IBEPE study). *Retina* 2006;26:1006-13.
- Romano MR, Gibran SK, Marticorena J, et al. Can a preoperative bevacizumab injection prevent recurrent postvitrectomy diabetic vitreous haemorrhage? *Eye* 2009;19:618-21
- Farrahi F, MD, Fegghi M, Bagherzadeh B. Sulfur Hexafluoride 20% versus Lactated Ringer's Solution for Prevention of Early Postoperative Vitreous Hemorrhage after Diabetic Vitrectomy. *J Ophthalmic Vis Res*. 2010 April; 5(2): 105-109.
- Novak MA, Rice TA, Michels RG, et al. Vitreous haemorrhage after vitrectomy for diabetic retinopathy. *Ophthalmology*. 1984 91:1485-1489.
- James FW, Zdenek J G. Fibrovascular ingrowth and recurrent haemorrhage following diabetic vitrectomy. *Br J Ophthalmol* 2000; 84:822-825.
- Brown GC, Tasman WS, Benson WE, et al. (1992) Re-operation following diabetic vitrectomy. *Arch Ophthalmol* 110:506-510.
- Rizzo S, Genovesi-Ebert F, Di Bartolo E, et al. Injection of intravitreal bevacizumab (Avastin) as a preoperative adjunct before vitrectomy surgery in the treatment of severe proliferative diabetic retinopathy (PDR). *Graefes Arch ClinExpOphthalmol* 2008; 246:837-42
- Joondeph BC, Blankenship GW. Hemostatic effects of air versus fluid in diabetic vitrectomy. *Ophthalmology*. 1989;



- 96 (12) :1701–6. discussion 6-7.
19. Koutsandrea CN, Apostolopoulos MN, Chatzoulis DZ, et al. Hemostatic effects of SF6 after diabetic vitrectomy for vitreous hemorrhage. *Acta Ophthalmol Scand*. 2001;79(1):34–8.
 20. Michels RG, Rice TA, Rice EF. Vitrectomy for diabetic vitreous hemorrhage. *Am J Ophthalmol*. 1983;95(1):12–21.
 21. Rice TA, Michels RG, Rice EF. Vitrectomy for diabetic traction retinal detachment involving the macula. *Am J Ophthalmol*. 1983;95(1):22–33.
 22. Diabetic Retinopathy Vitrectomy Study (DRVS). Two-year course of visual acuity in severe proliferative diabetic retinopathy with conventional management. Report no 1. *Ophthalmology* 1985; 92:492–502.